

# CAT'S EYE CAUGHT ON CAMERA – A CASE OF UNILATERAL RETINOBLASTOMA DIAGNOSED THROUGH PARENTAL OBSERVATION OF LEUKOCORIA

<sup>1</sup>DR. PAVITHRA. V

<sup>2</sup>DR. KAVIYA .S

<sup>3</sup>DR. DIVYA N

<sup>4</sup>DR. PANIMALAR. A. VEERAMANI

<sup>5</sup>DR. MYTHRIYEE B. G

<sup>1</sup>DEPARTMENT OF OPHTHALMOLOGY, SAVEETHA MEDICAL COLLEGE AND HOSPITALS, SAVEETHA INSTITUTE OF MEDICAL AND TECHNICAL SCIENCES, SAVEETHA UNIVERSITY · CHENNAI, IND

<sup>2</sup>DEPARTMENT OF OPHTHALMOLOGY, SAVEETHA MEDICAL COLLEGE AND HOSPITALS, SAVEETHA INSTITUTE OF MEDICAL AND TECHNICAL SCIENCES, SAVEETHA UNIVERSITY · CHENNAI, IND

<sup>3</sup>DEPARTMENT OF OPHTHALMOLOGY, SAVEETHA MEDICAL COLLEGE AND HOSPITALS, SAVEETHA INSTITUTE OF MEDICAL AND TECHNICAL SCIENCES, SAVEETHA UNIVERSITY · CHENNAI, IND

<sup>4</sup>DEPARTMENT OF OPHTHALMOLOGY, SAVEETHA MEDICAL COLLEGE AND HOSPITALS, SAVEETHA INSTITUTE OF MEDICAL AND TECHNICAL SCIENCES, SAVEETHA UNIVERSITY · CHENNAI, IND

<sup>5</sup>SENIOR LECTURER, DEPARTMENT OF ORTHODONTICS & DENTOFACIAL ORTHOPEDICS, SREE BALAJI DENTAL COLLEGE & HOSPITAL, CHENNAI, INDIA

## Abstract:

Retinoblastoma is the most common intraocular malignancy in children and frequently presents with leukocoria, a white pupillary reflex that is often first noticed by caregivers in photographs. This case highlights the pivotal role of early parental observation in diagnosing a potentially life-threatening yet treatable malignancy.

We report the case of an 8-month-old male infant whose mother noticed a white reflex in the right eye while reviewing family photographs. Clinical examination, ultrasonography, and magnetic resonance imaging (MRI) revealed a solitary, endophytic retinoblastoma with focal vitreous and subretinal seeding. The lesion was categorized as Group C according to the International Classification of Intraocular Retinoblastoma (ICRB). The child was commenced on a systemic chemotherapy protocol (JOE: Carboplatin, Vincristine, and Etoposide) as part of a chemo-reduction strategy aimed at preserving the globe and vision. The case underscores the importance of early detection, appropriate imaging, and multidisciplinary management in achieving optimal outcomes.

## INTRODUCTION

The most common primary intraocular cancer in children is retinoblastoma, a malignant tumor that originates from the retina (1) (2). It usually manifests before the age of five and accounts for about 3% of all juvenile cancers(3). Biallelic inactivation of the RB1 tumor suppressor gene, which is found on chromosome 13q14, causes the disorder (4)(2). The majority of unilateral instances are sporadic and include somatic mutations, whereas germline mutations cause bilateral or multifocal disease and follow an autosomal dominant inheritance pattern(5)(6).

Retinoblasts, which are primitive retinal precursor cells that are often present during early retinal development, are thought to be the tumour's genesis (7)(8)(9). Leukocoria, strabismus, reduced visual behaviour, and, in more advanced cases, indications of orbital extension such as proptosis or painful red eye are among the clinical manifestations of retinoblastoma, which vary depending on the stage (10).

This study demonstrates the imaging, classification, and treatment approaches used in a case of unilateral retinoblastoma detected at an early stage and highlights the critical relevance of early diagnosis, especially through caregiver awareness.

## Case Report:

When his mother spotted a white reaction in his right eye during routine photography, the 8-month-old boy was brought to our ophthalmology outpatient department with the main complaint. Symptoms including redness, discharge, or visual inattention were absent. There was no family history of cancer or eye disease, and the youngster did not exhibit any systemic complaints or developmental delays.

On clinical examination, the left eye (LE) seemed normal, but the right eye (RE) had leukocoria. Bilateral preservation of visual behaviour, including fixation and tracking of light stimuli, suggests that visual potential was intact.

Upon fundus examination, a massive, raised, cream-white mass roughly five disc diameters in size was found temporally to the optic disc in the right eye. The retinal elevation and uneven margins of the tumour were indicative of an endophytic development pattern. A distinct intraocular mass with high internal reflectivity and intralesional calcifications—a characteristic of retinoblastoma—was seen on B-scan ultrasonography. Localized exudative retinal detachment, subretinal seeds measuring 2.02 mm, and vitreous seeds up to 3.36 mm were among the related findings. To exclude out extraocular and cerebral extension, a brain and orbital MRI was conducted. There was no involvement of the optic nerve or central nervous system, and the lesion showed up as hyperintense on T1-weighted and hypointense on T2-weighted sequences. Analysis of the cerebrospinal fluid (CSF) and bone marrow aspirate revealed no evidence of metastatic involvement.

The lesion was identified as Group C by the ICRB, which denotes a circumscribed disease with little vitreous and subretinal seeding. In order to reduce the size of the tumour and control seeding before local consolidative therapy, the youngster was started on systemic chemo-reduction utilizing the JOE regimen (Carboplatin, Vincristine, and Etoposide). To guarantee comprehensive and dynamic care, constant coordination with the radiology, ocular oncology, and pediatric oncology departments was maintained.

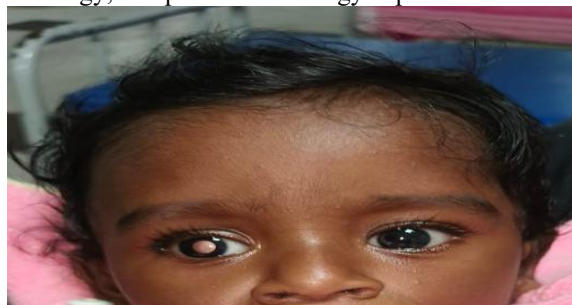

FIGURE 1: Leukocoria noted in right eye

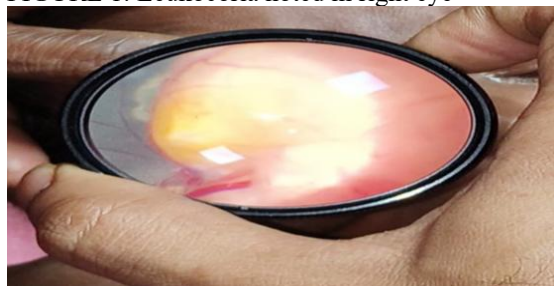

FIGURE 2 : whitish elevated mass noted in the posterior pole temporal to the disc of 5 DD.

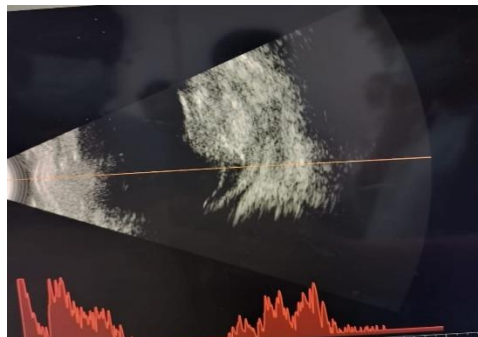


FIGURE 3: Hyperechoic mass like lesion with intra lesional calcification noted in VC. RD+. Sub retinal seeding 2.02 mm. Vitreous seeding 3.36 mm.

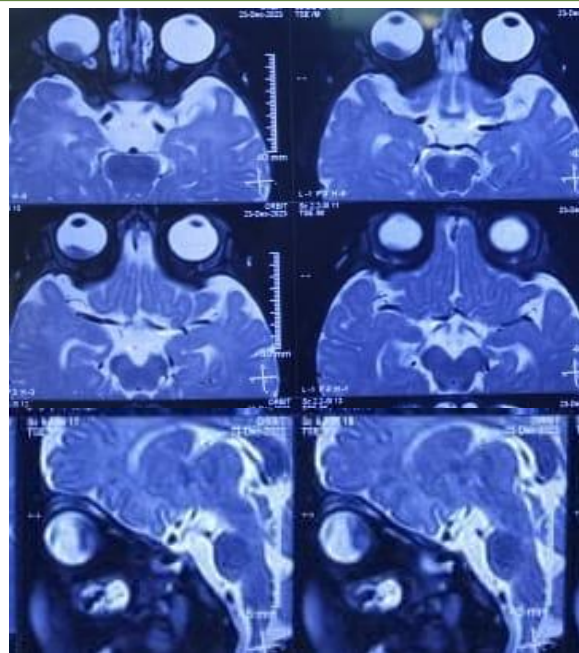


FIGURE 4 : MRI orbit- T1 hyper intense, T2 hypointense lesion noted in VC s/o Endophytic Retinoblastoma

## DISCUSSION

Early detection of retinoblastoma is crucial because it is a treatable cancer. Unilateral retinoblastoma, like the one in this instance, usually manifests between 18 and 30 months of age(11), but bilateral ones usually do so around 12 months(12). But because to careful parental watch, this case was identified at just 8 months, highlighting the need of public education and caregiver awareness(13).

The most prevalent presenting symptom, leukocoria, is frequently initially observed in flash photos, a phenomenon known as the "cat's eye reflex." The second most common indication is strabismus(14)(15). Children may less frequently exhibit hypopyon, stinging red eyes, or symptoms of advanced disease such as proptosis(16)(17).

In order to assess the tumour's size, location, extent, and presence of calcification, as well as to rule out optic nerve invasion or cerebral dissemination, the diagnostic workup consists of fundus examination, B-scan ultrasonography, and MRI of the brain and orbits(18). The ideal method for assessing soft tissue and central nervous system involvement is magnetic resonance imaging (MRI) rather than computed tomography (CT)(19).

Tumour laterality, group classification, and disease severity all affect treatment. For early and middle groups, options include systemic chemotherapy (chemo-reduction)(20)(21).

- In certain situations, particularly when systemic therapy is ineffective, intra-arterial chemotherapy (IAC) may be used(22).
- Chemotherapy administered intravitreally for persistent vitreous seeding(23).
- Focused treatments like cryotherapy, thermotherapy, and laser photocoagulation.
- Enucleation, if the eye is life-threatening or vision cannot be maintained.

Systemic chemotherapy with the JOE regimen has demonstrated good response rates and manageable adverse profiles in Group C eyes. By lowering the tumor burden, this method frequently makes focused therapy more effective and avoids the need for enucleation(24).

For best results, a multidisciplinary strategy comprising radiologists, genetic counselors, paediatric oncologists, ophthalmologists, and rehabilitation teams is necessary. In unilateral situations, genetic evaluation is also essential to determine the danger to siblings or future children(25).

## CONCLUSION

This instance highlights how important it is to identify leukocoria in infants early on, as it may be the first obvious symptom of a potentially fatal illness like retinoblastoma. Global and vision preservation becomes a feasible objective with early diagnosis and adequate treatment, which frequently starts with systemic chemo-reduction. Furthermore, the

prognosis of this uncommon but dangerous ocular tumour can be greatly impacted by parent education, regular eye examination, and raised awareness among pediatricians and general practitioners. In pediatric ocular oncology, persistent support for early detection and prompt intervention is still essential.

## REFERENCES

1. Larrosa C, Simao-Rafael M, Salvador N, Muñoz JP, Lavarino C, Chantada G, et al. Case Report: Successful treatment of metastatic retinoblastoma with CNS involvement with anti-GD2 immunotherapy, intrathecal topotecan and reduced systemic chemotherapy. *Front Pediatr*. 2024;12:1509645.
2. Website [Internet]. Available from: Zhou, L., Zhu, X. H., Zhang, K., Hu, R., & Myers, F. (2020). Case Report: Adult Retinoblastoma Progression in 19 Months. *Optometry and vision science : official publication of the American Academy of Optometry*, 97(11), 1010–1016. <https://doi.org/10.1097/OPX.0000000000001602>
3. Website [Internet]. Available from: Park, J. J., Gole, G. A., Finnigan, S., & Vandeleur, K. (1999). Late presentation of a unilateral sporadic retinoblastoma in a 16-year-old girl. *Australian and New Zealand journal of ophthalmology*, 27(5), 365–368. <https://doi.org/10.1046/j.1440-1606.1999.00217.x>
4. Website [Internet]. Available from: Biswas, J., Mani, B., Shanmugam, M. P., Patwardhan, D., Kumar, K. S., & Badrinath, S. S. (2000). Retinoblastoma in adults. Report of three cases and review of the literature. *Survey of ophthalmology*, 44(5), 409–414. [https://doi.org/10.1016/s0039-6257\(99\)00132-0](https://doi.org/10.1016/s0039-6257(99)00132-0)
5. Website [Internet]. Available from: Decaussin, M., Boran, M. D., Salle, M., Grange, J. D., Patricot, L. M., & Thivolet-Bejui, F. (1998). Cytological aspiration of intraocular retinoblastoma in an 11-year-old boy. *Diagnostic cytopathology*, 19(3), 190–193. [https://doi.org/10.1002/\(sici\)1097-0339\(199809\)19:3<190::aid-dc7>3.0.co;2-h](https://doi.org/10.1002/(sici)1097-0339(199809)19:3<190::aid-dc7>3.0.co;2-h)
6. Website [Internet]. Available from: Hasan, S. J., Brooks, M., Ambati, J., Kielar, R., & Stevens, J. L. (2003). Retinoblastoma with cataract and ectopia lentis. *Journal of AAPOS : the official publication of the American Association for Pediatric Ophthalmology and Strabismus*, 7(6), 425–427. <https://doi.org/10.1016/j.jaapos.2003.07.005>
7. Website [Internet]. Available from: Lueder, G. T., Grosten, R., & Smith, M. (2001). Pathological case of the month. Retinoblastoma presenting as pseudiritis and secondary glaucoma. *Archives of pediatrics & adolescent medicine*, 155(4), 519–520. <https://doi.org/10.1001/archpedi.155.4.519>
8. Website [Internet]. Available from: Odashiro, A. N., Pereira, P. R., de Souza Filho, J. P., Cruess, S. R., & Burnier, M. N., Jr (2005). Retinoblastoma in an adult: case report and literature review. *Canadian journal of ophthalmology. Journal canadien d'ophtalmologie*, 40(2), 188–191. [https://doi.org/10.1016/S0008-4182\(05\)80032-8](https://doi.org/10.1016/S0008-4182(05)80032-8)
9. Website [Internet]. Available from: Belt, P. J., Smithers, M., & Elston, T. (2002). The triad of bilateral retinoblastoma, dysplastic naevus syndrome and multiple cutaneous malignant melanomas: a case report and review of the literature. *Melanoma research*, 12(2), 179–182. <https://doi.org/10.1097/00008390-200204000-00012>
10. Website [Internet]. Available from: Rollins N. K. (2023). Association between MRI Findings and Causative Variations in Unilateral Retinoblastoma. *Radiology*, 307(5), e230852. <https://doi.org/10.1148/radiol.230852>
11. Schuurs A. *Pathology of the Hard Dental Tissues*. Wiley-Blackwell; 2012. 456 p.
12. Website [Internet]. Available from: Fabian, I. D., Naeem, Z., Stacey, A. W., Chowdhury, T., Duncan, C., Reddy, M. A., & Sagoo, M. S. (2017). Long-term Visual Acuity, Strabismus, and Nystagmus Outcomes Following Multimodality Treatment in Group D Retinoblastoma Eyes. *American journal of ophthalmology*, 179, 137–144. <https://doi.org/10.1016/j.ajo.2017.05.003>
13. Website [Internet]. Available from: Shields C. L. (2008). Forget-me-nots in the care of children with retinoblastoma. *Seminars in ophthalmology*, 23(5), 324–334. <https://doi.org/10.1080/08820530802506029>
14. Website [Internet]. Available from: Masoomian, B., Shields, C. L., Esfahani, H. R., Khalili, A., Ghassemi, F., Rishi, P., Akbari, M. R., & Khorrami-Nejad, M. (2024). Strabismus management in retinoblastoma survivors. *BMC ophthalmology*, 24(1), 114. <https://doi.org/10.1186/s12886-024-03379-9>
15. Website [Internet]. Available from: Fabian, I. D., Stacey, A. W., Naeem, Z., Onadim, Z., Chowdhury, T., Duncan, C., Sagoo, M. S., & Reddy, M. A. (2018). Strabismus in retinoblastoma survivors with long-term follow-up. *Journal of AAPOS : the official publication of the American Association for Pediatric Ophthalmology and Strabismus*, 22(4), 276.e1–276.e7. <https://doi.org/10.1016/j.jaapos.2018.03.007>
16. Website [Internet]. Available from: Rosselet, E., Gailloud, C., & Verrey, F. (1970). Rétinoblastome et hypopyon (Epilogue) [Retinoblastoma and hypopyon]. *Ophthalmologica. Journal international d'ophtalmologie. International journal of ophthalmology. Zeitschrift für Augenheilkunde*, 161(2), 139–144. <https://doi.org/10.1159/000306104>
17. Website [Internet]. Available from: Walton, D. S., & Grant, W. M. (1968). Retinoblastoma and iris

- neovascularization. *American journal of ophthalmology*, 65(4), 598–599. [https://doi.org/10.1016/0002-9394\(68\)93882-8](https://doi.org/10.1016/0002-9394(68)93882-8)
18. Website [Internet]. Available from: Gündüz, K., Günalp, I., Yalçındağ, N., Unal, E., Taçyıldız, N., Erden, E., & Geyik, P. O. (2004). Causes of chemoreduction failure in retinoblastoma and analysis of associated factors leading to eventual treatment with external beam radiotherapy and enucleation. *Ophthalmology*, 111(10), 1917–1924. <https://doi.org/10.1016/j.ophtha.2004.04.016>
19. Website [Internet]. Available from: Shields, C. L., Ramasubramanian, A., Thangappan, A., Hartzell, K., Leahey, A., Meadows, A. T., & Shields, J. A. (2009). Chemoreduction for group E retinoblastoma: comparison of chemoreduction alone versus chemoreduction plus low-dose external radiotherapy in 76 eyes. *Ophthalmology*, 116(3), 544–551.e1. <https://doi.org/10.1016/j.ophtha.2008.10.014>
20. Website [Internet]. Available from: Shields, C. L., Mashayekhi, A., Au, A. K., Czyz, C., Leahey, A., Meadows, A. T., & Shields, J. A. (2006). The International Classification of Retinoblastoma predicts chemoreduction success. *Ophthalmology*, 113(12), 2276–2280. <https://doi.org/10.1016/j.ophtha.2006.06.018>
21. Website [Internet]. Available from: Shields, C. L., & Shields, J. A. (2006). Basic understanding of current classification and management of retinoblastoma. *Current opinion in ophthalmology*, 17(3), 228–234. <https://doi.org/10.1097/01.icu.0000193079.55240.18>
22. Website [Internet]. Available from: Lumbroso-Le Rouic, L., Aerts, I., Lévy-Gabriel, C., Dendale, R., Sastre, X., Esteve, M., Asselain, B., Bours, D., Doz, F., & Desjardins, L. (2008). Conservative treatments of intraocular retinoblastoma. *Ophthalmology*, 115(8), 1405–1410.e14102. <https://doi.org/10.1016/j.ophtha.2007.11.009>
23. Papaliodis GN. *Uveitis: A Practical Guide to the Diagnosis and Treatment of Intraocular Inflammation*. Springer; 2017. 354 p.
24. Website [Internet]. Available from: Lin, P., & O'Brien, J. M. (2009). Frontiers in the management of retinoblastoma. *American journal of ophthalmology*, 148(2), 192–198. <https://doi.org/10.1016/j.ajo.2009.04.004>
25. Website [Internet]. Available from: Sovinz, P., Urban, C., Lackner, H., Benesch, M., & Langmann, G. (2006). Retinoblastoma: a proposal for a multimodal treatment concept for intraocular retinoblastoma in Austria. *Wiener klinische Wochenschrift*, 118(1-2), 22–30. <https://doi.org/10.1007/s00508-005-0503-z>